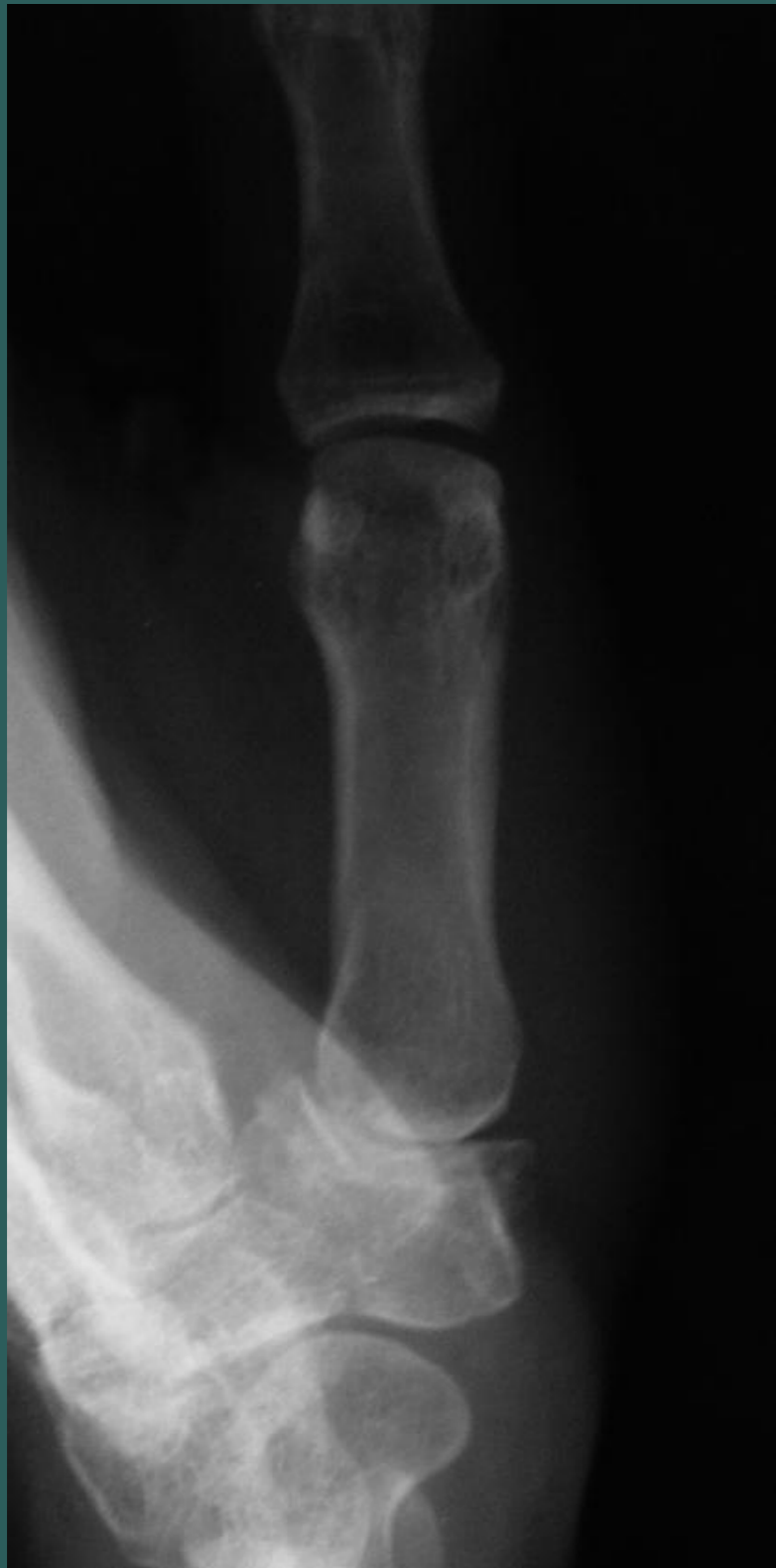
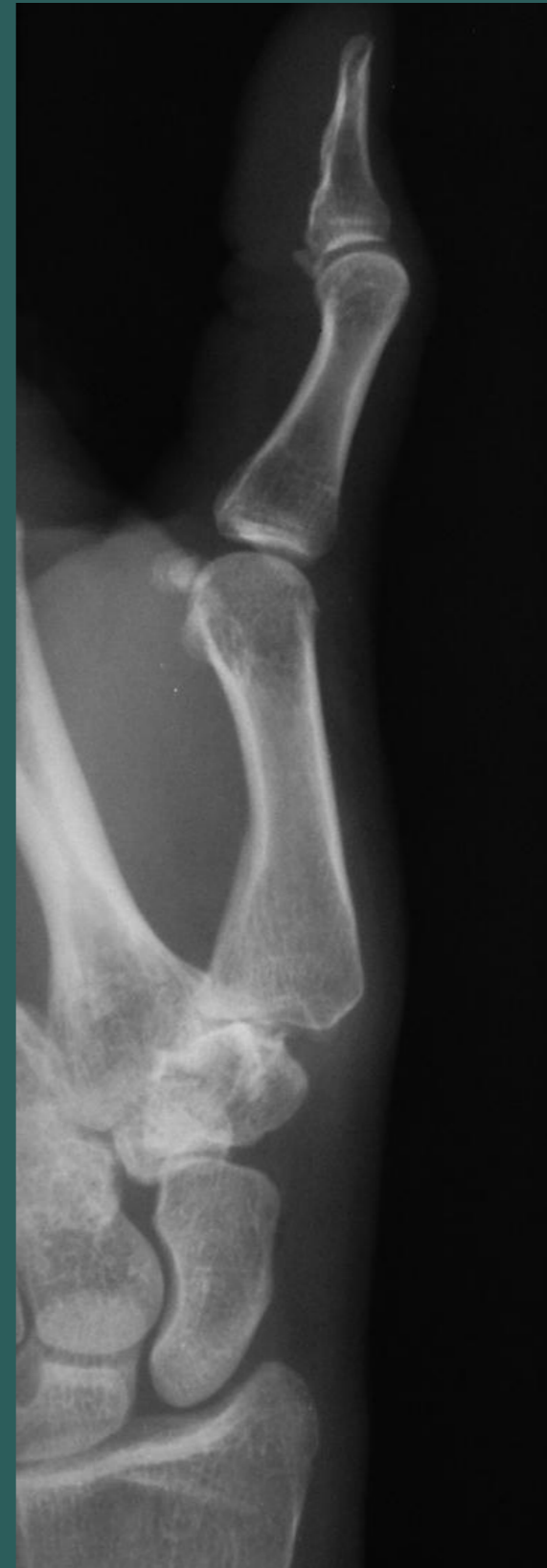


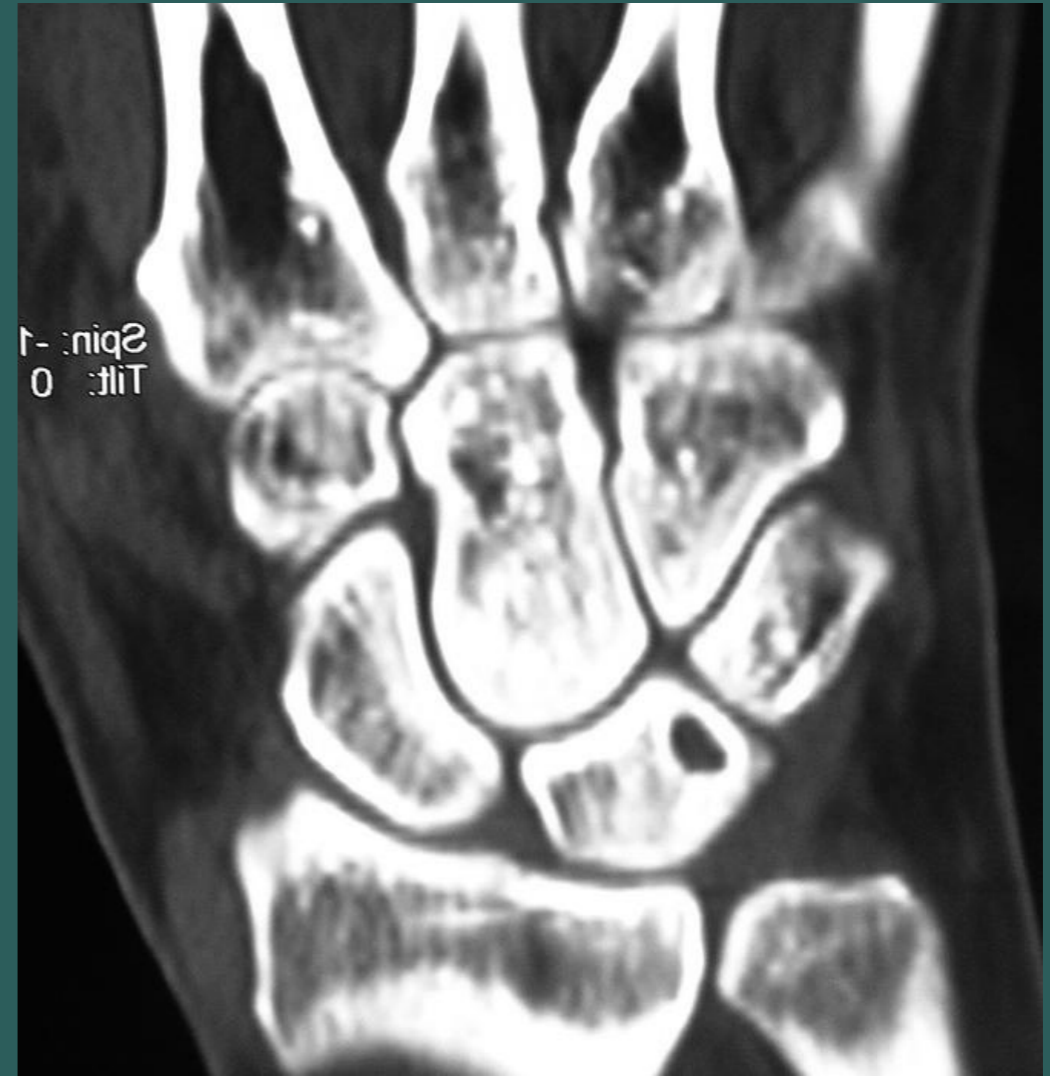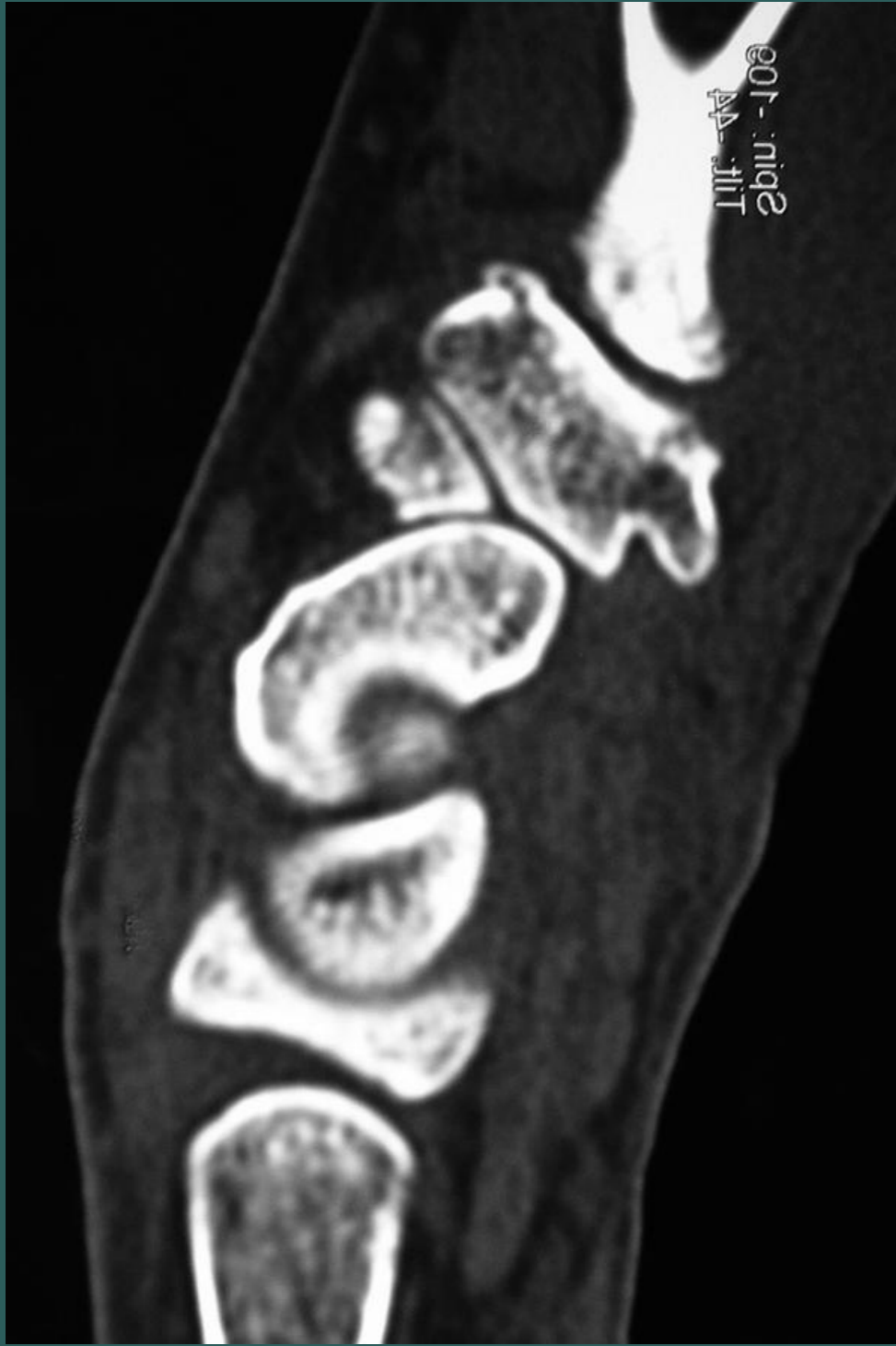52 y.
Woman
Right
Nurse

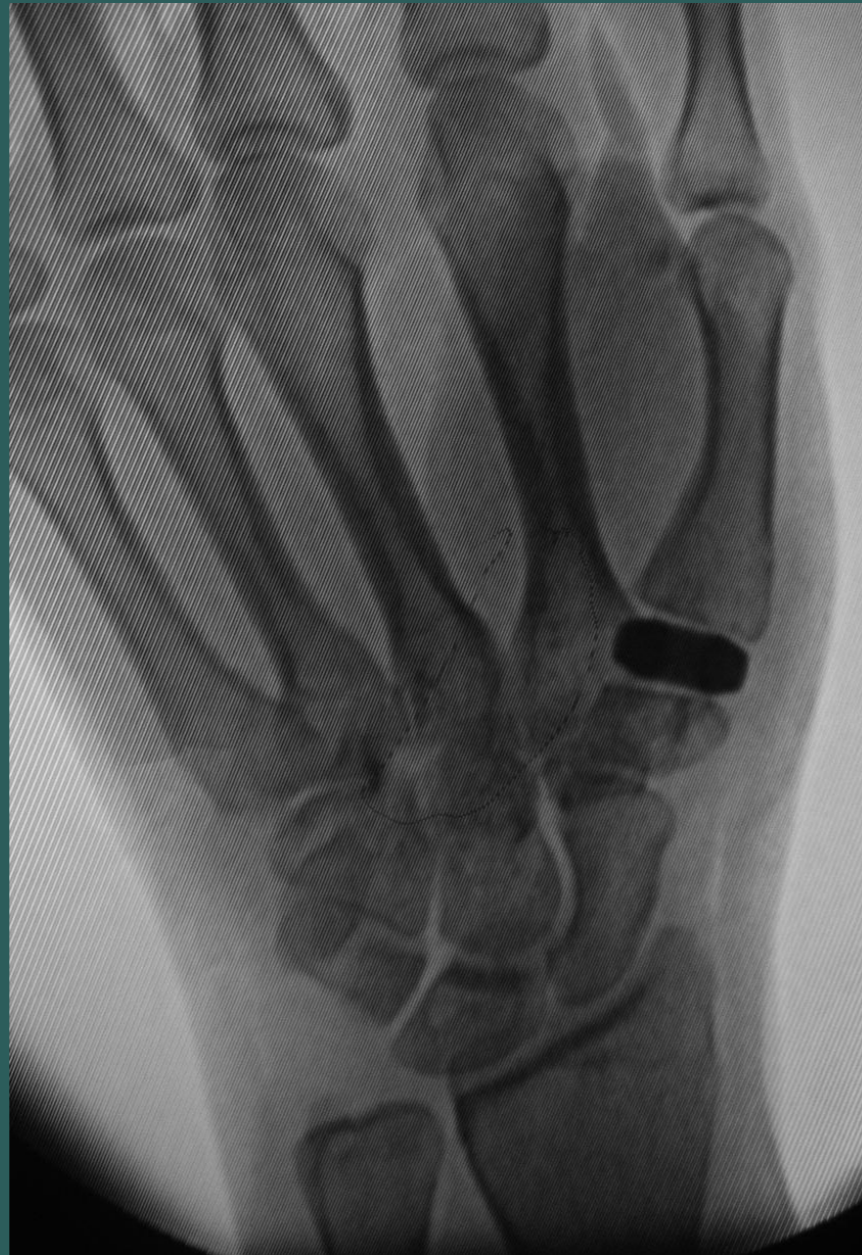Stage 1



No stt involvement !

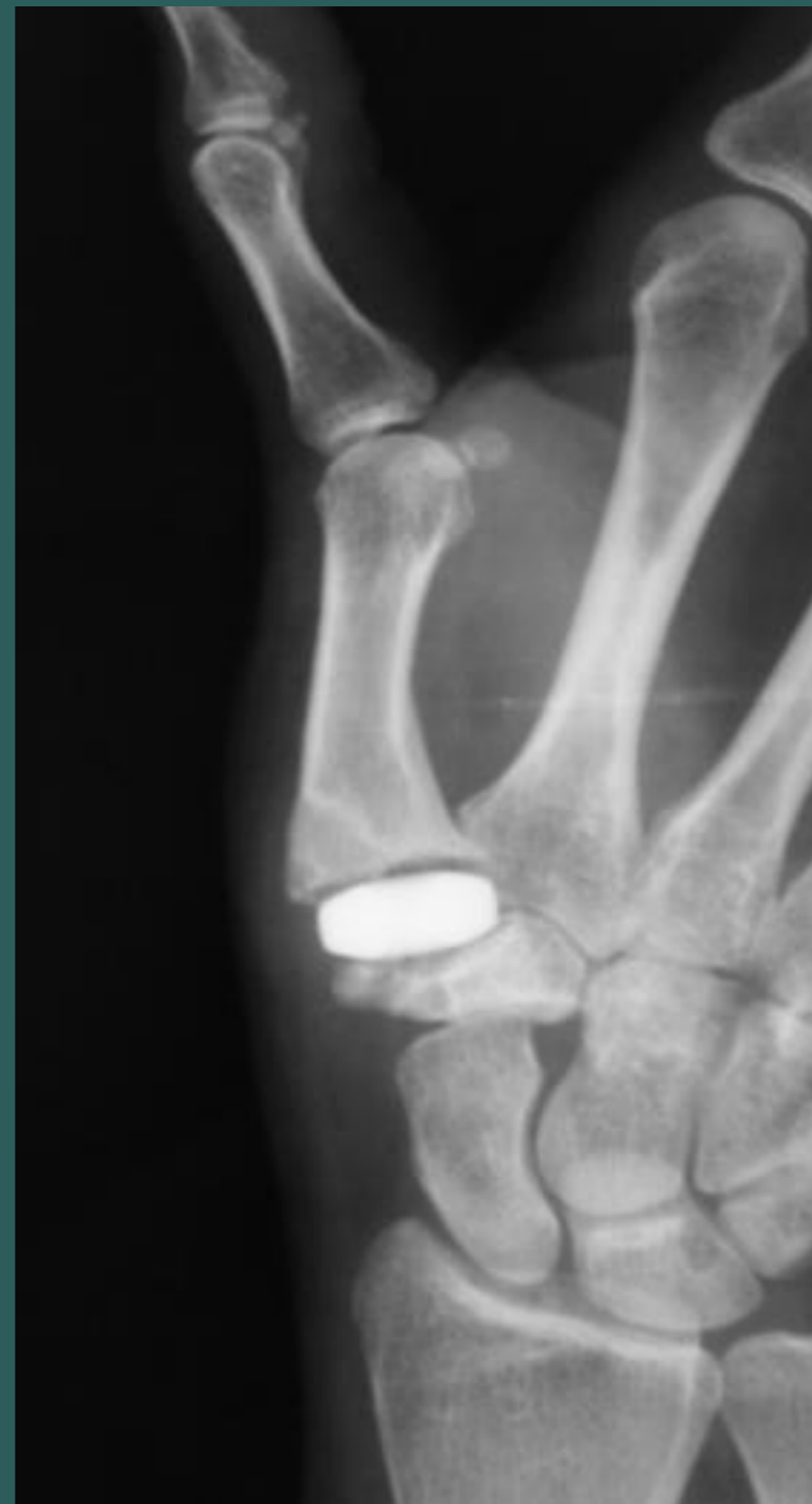
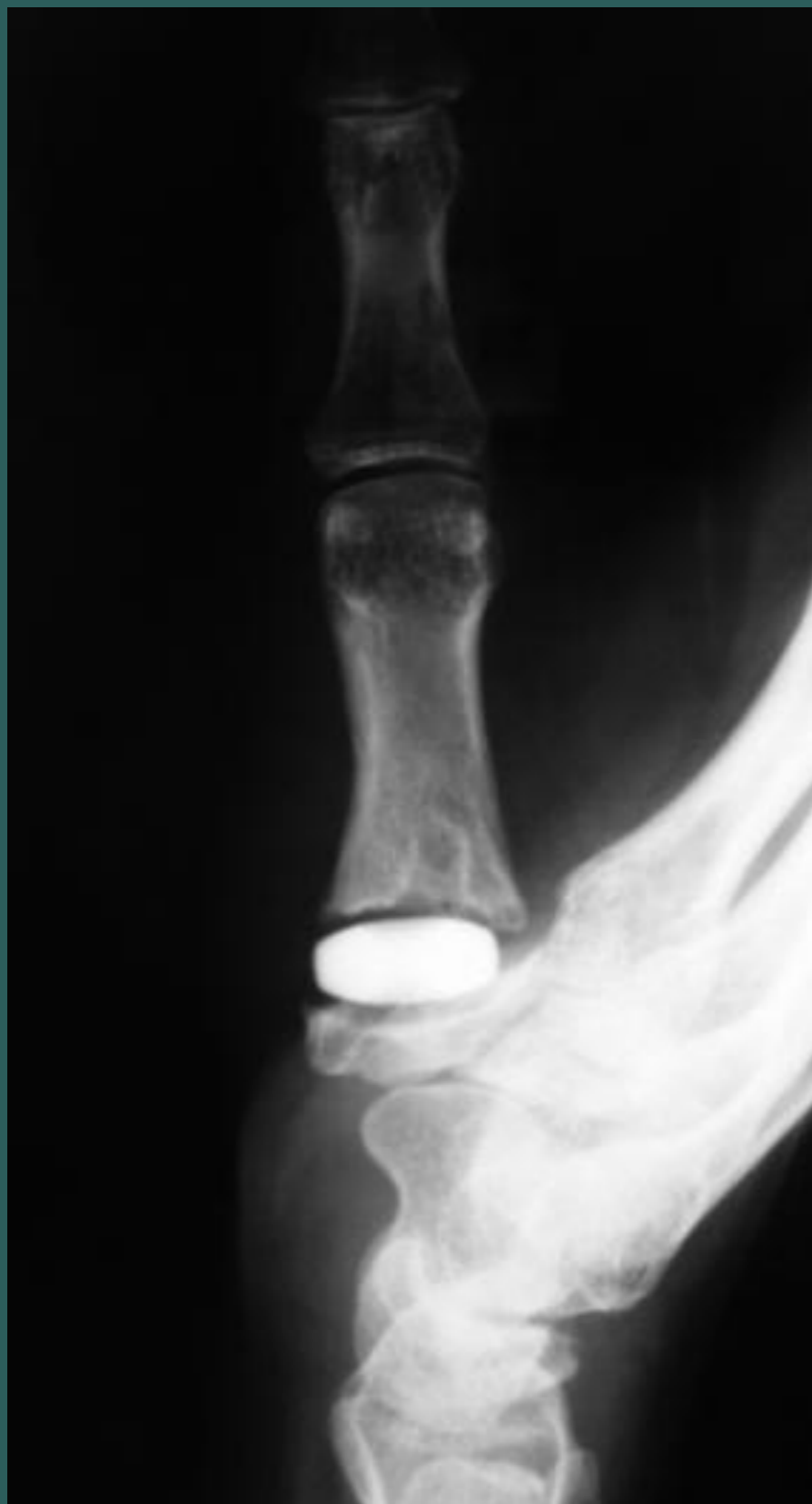
INTRAOP.



June 2006

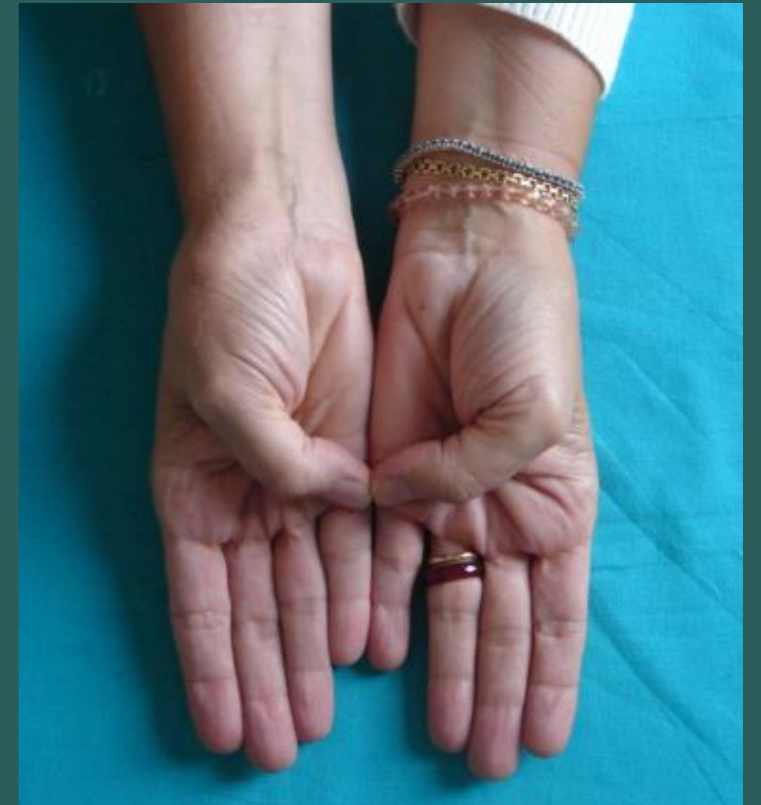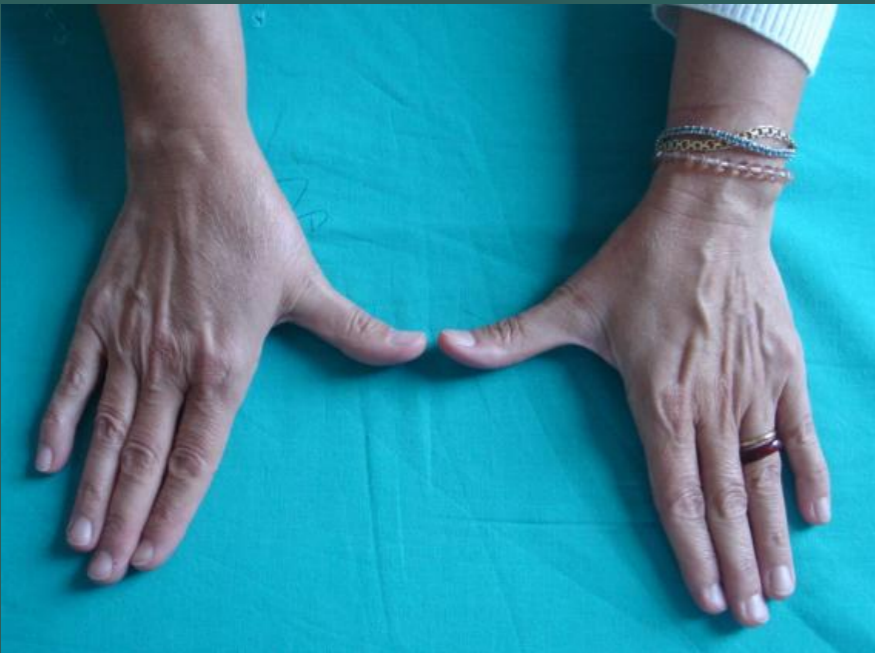
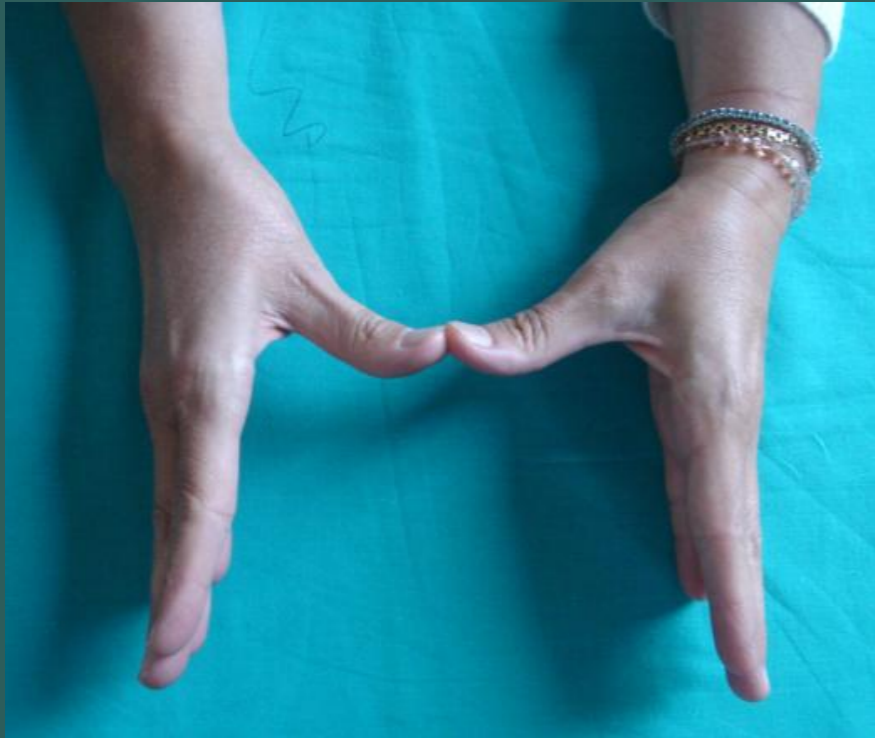15 months

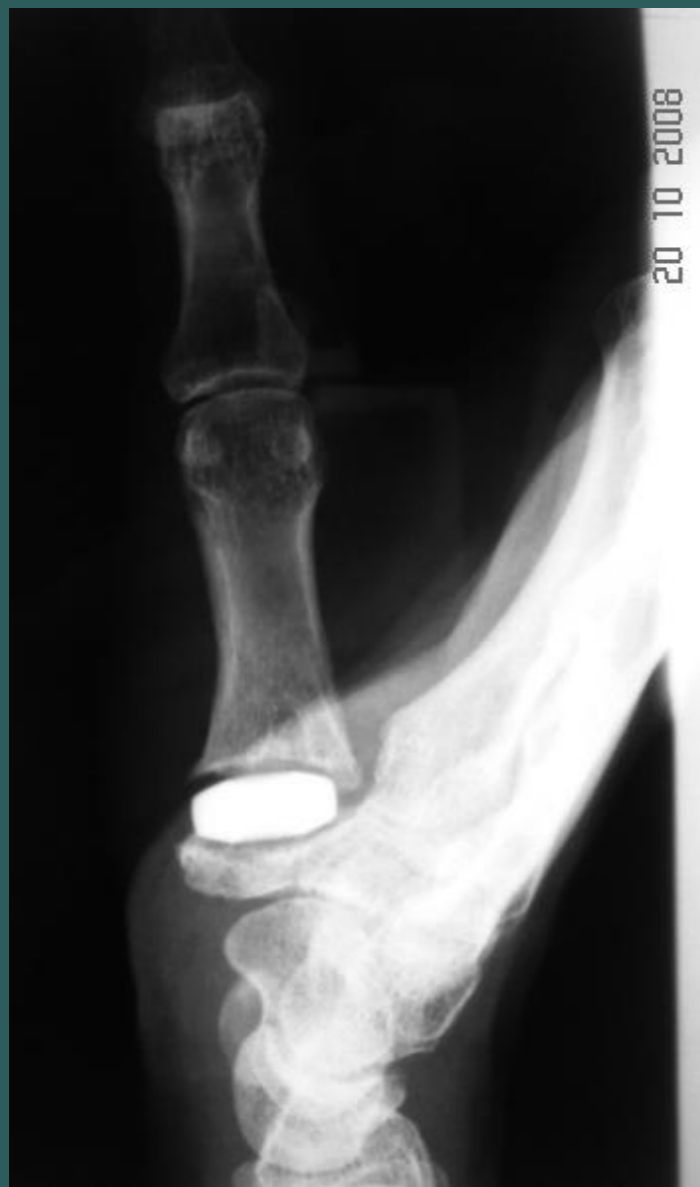

15 months

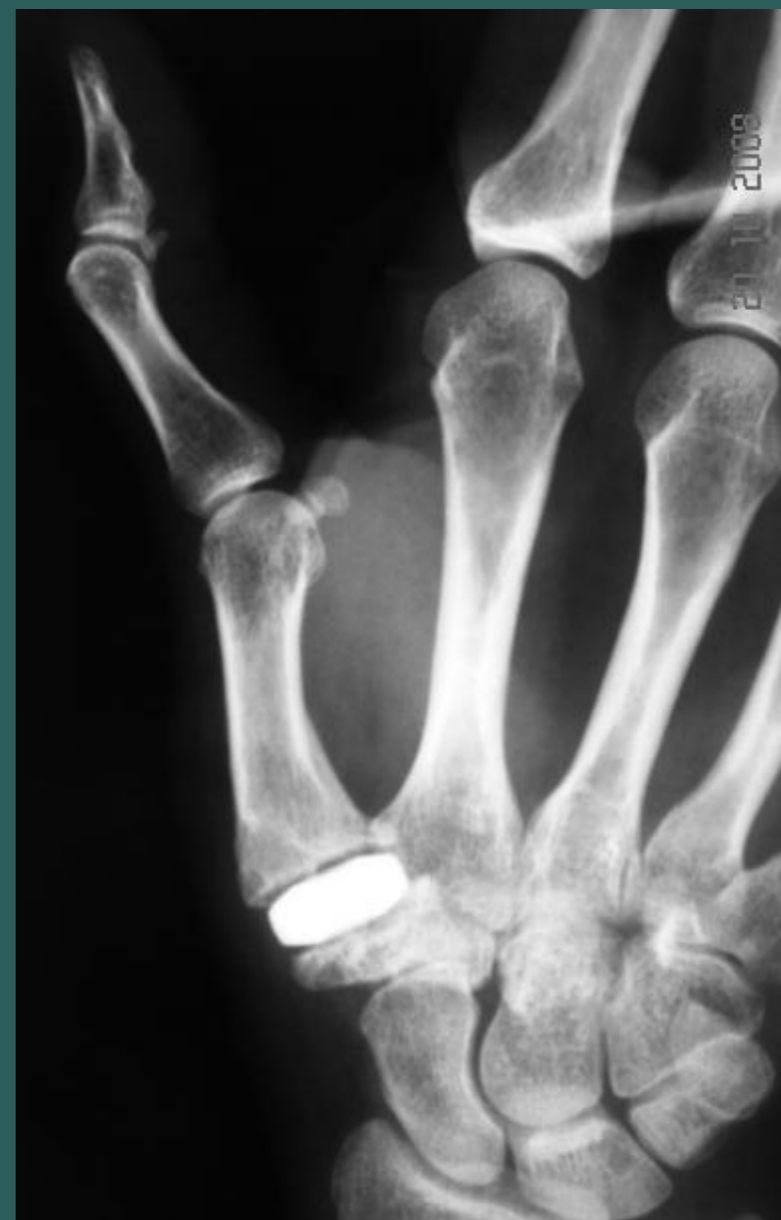Very satisfied !

Pain
vas: 0





28 MONTHS

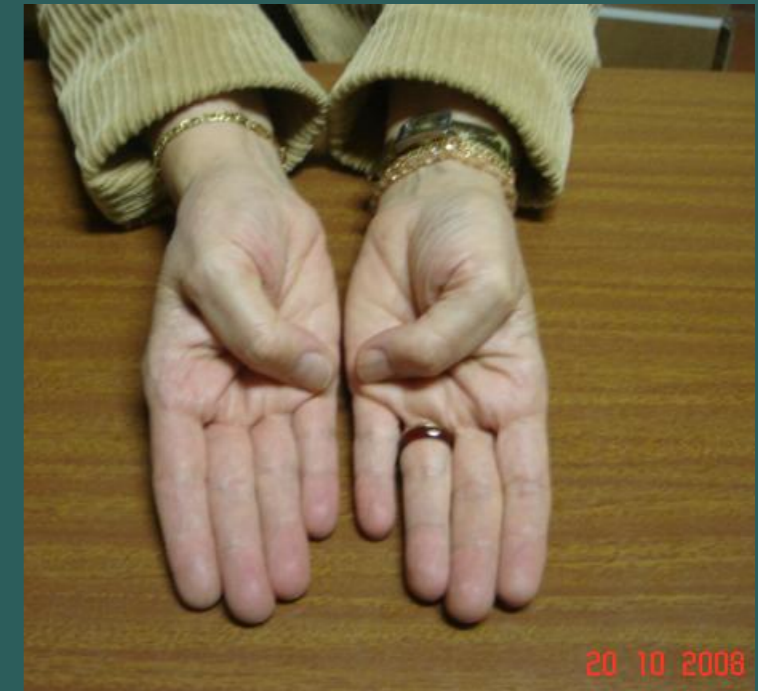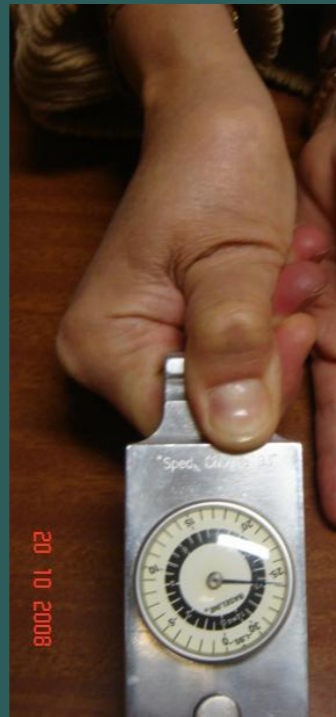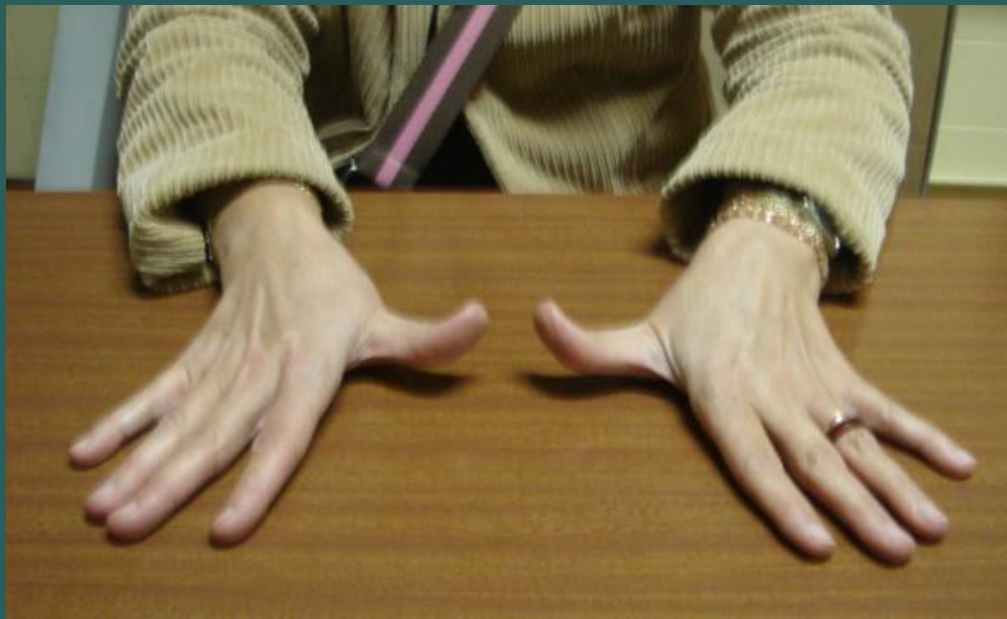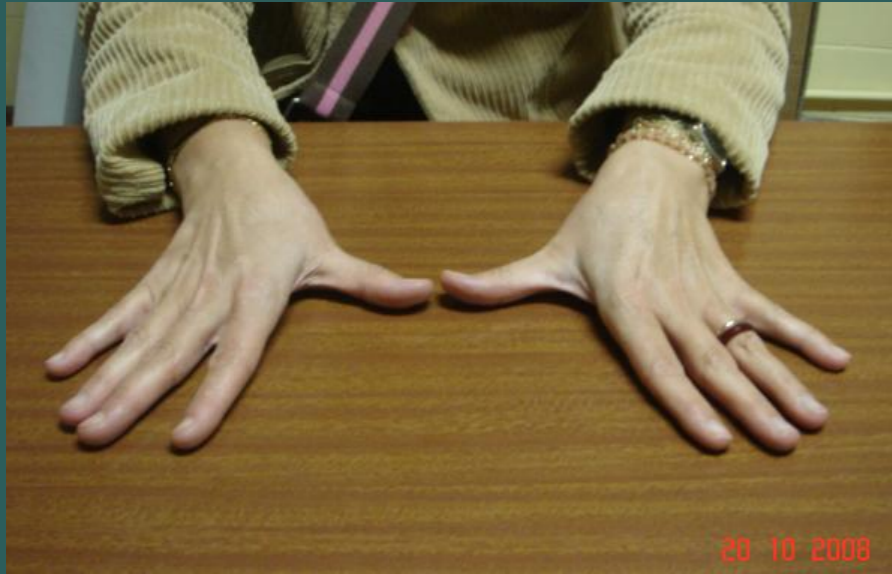


28 months

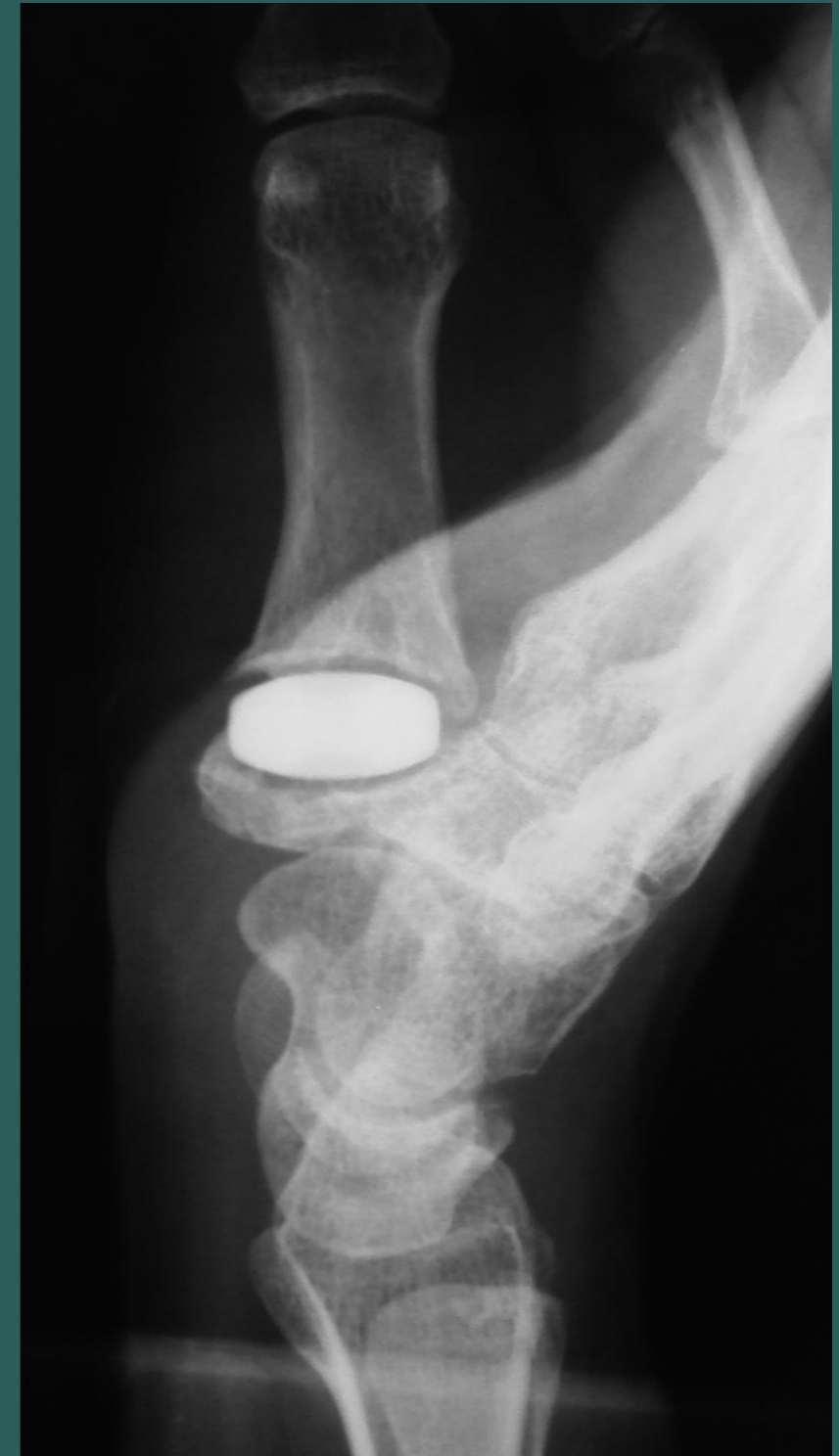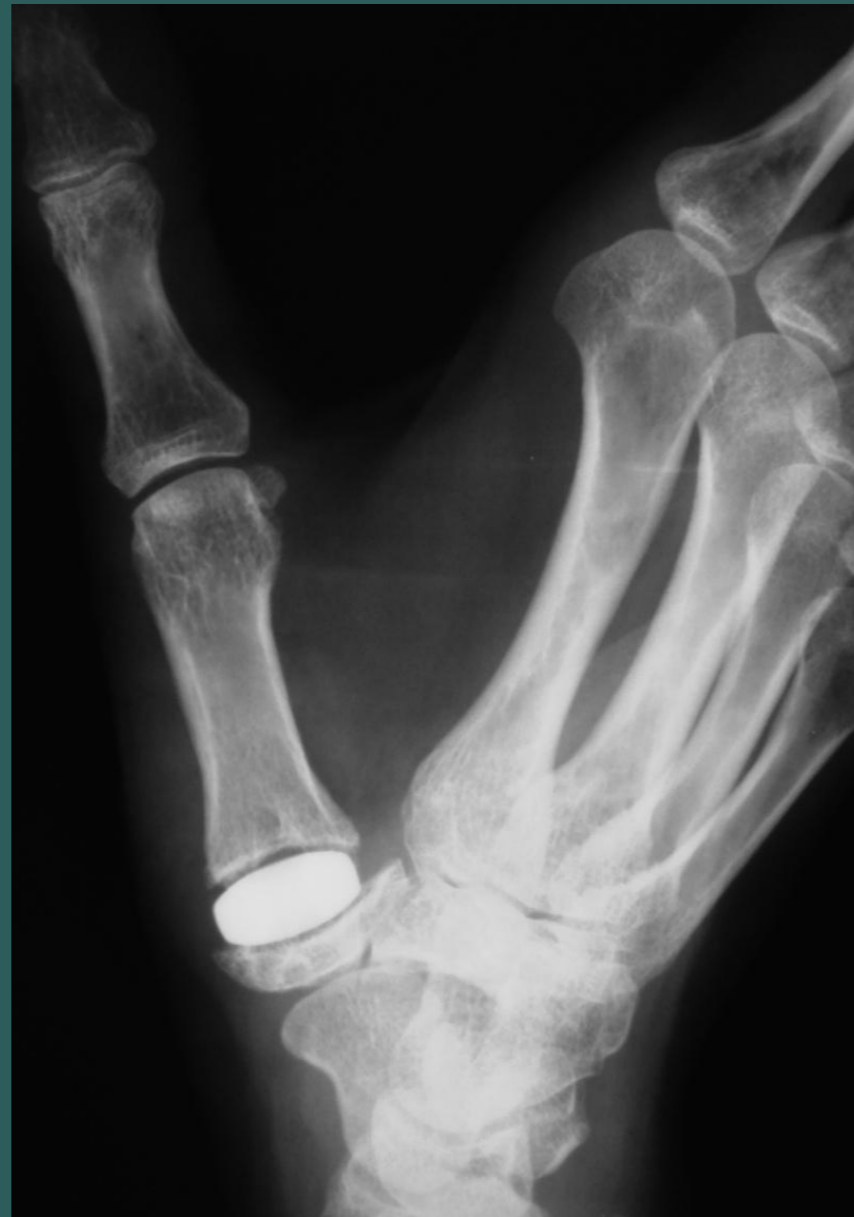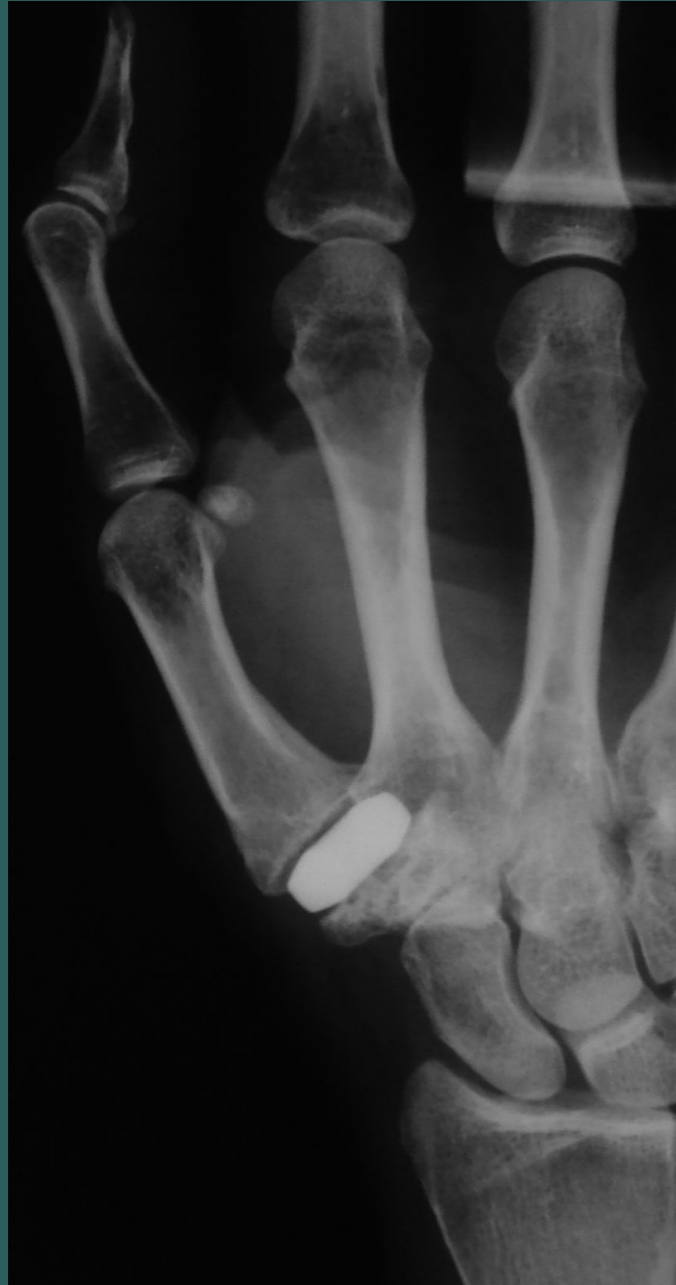Very satisfied

Pain

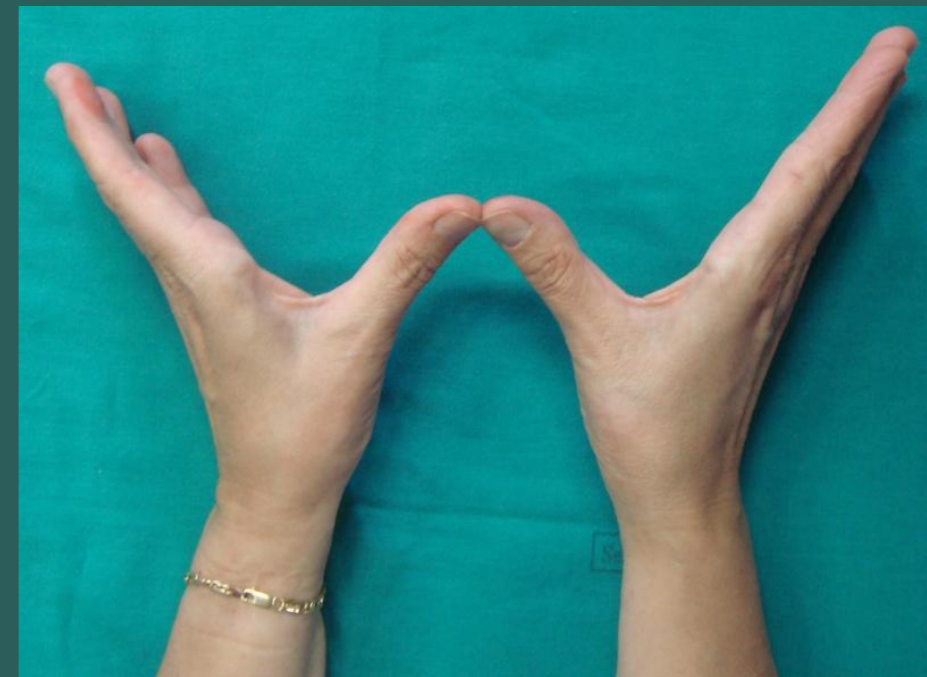
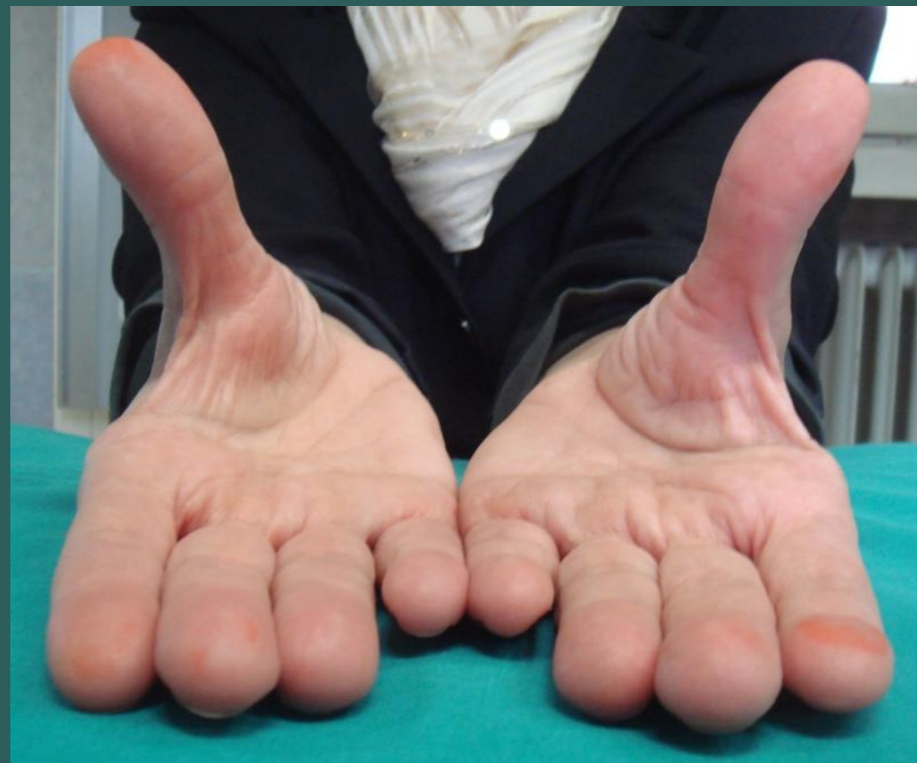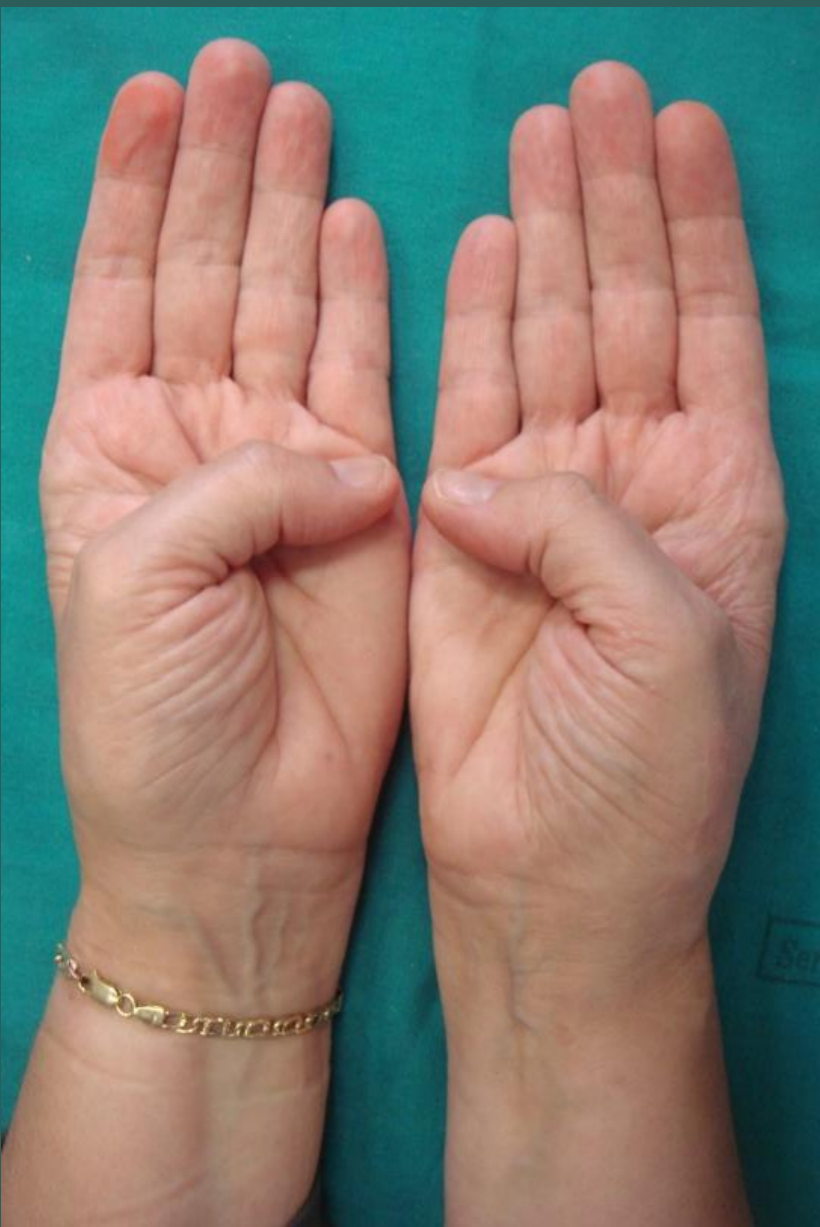vas: 0



4,3 YEARS



4,3 YEARS



VERY SATISFIED !

VAS: 0

GRIP: the same as controlateral !